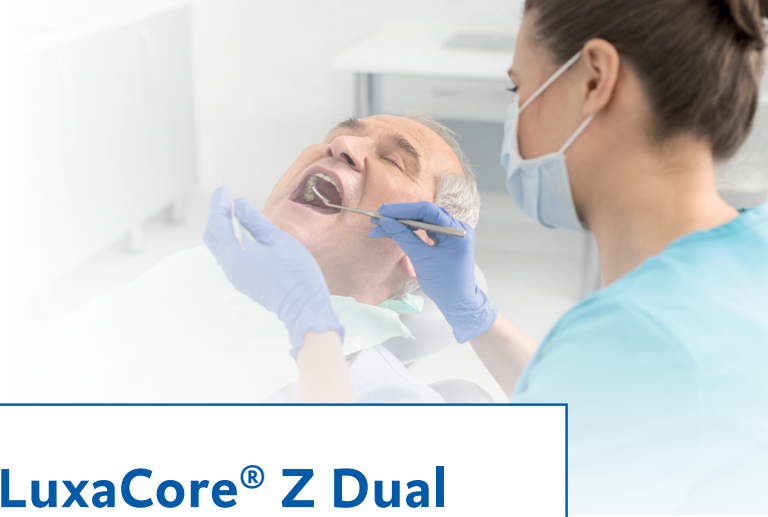



# QUICK CASE: Dr. Gary Radz



↖ **Ecosite Bulk Fill** ↖ **LuxaCore® Z Dual**  
↗ **Honigum Pro**

## OVERVIEW

↖ Composite restoration using **Ecosite Bulk Fill**, **LuxaCore Z Dual** and **Honigum Pro**

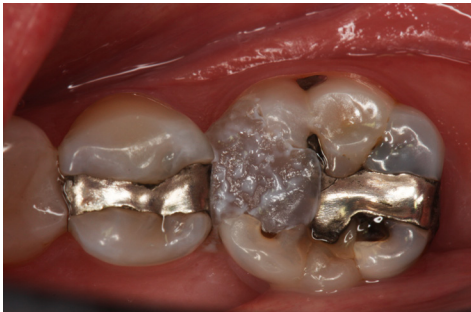

PHOTO #1

### PHOTO #1

- ↖ #29 - Large failing MOD amalgam, radiographic recurrent mesial decay
- ↖ #30 - Large amalgam present as well as temporary restoration on the mesial and structurally compromised to the point where a build up and crown are necessary

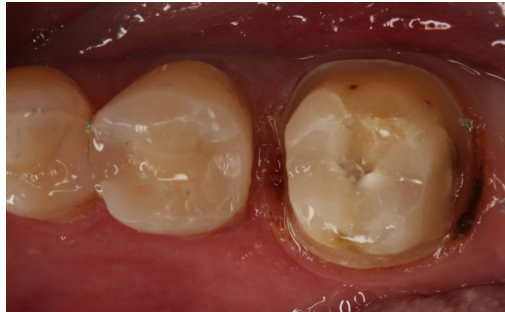

PHOTO #2

### PHOTO #2

- ↖ #29 - Restored with an MOD restoration using **Ecosite Bulk Fill** (universal)
- ↖ #30 - Old restorations were removed, recurrent decay was excavated, the tooth was restored with a build up (**LuxaCore Z Dual - A2**) and prepared for a zirconia crown

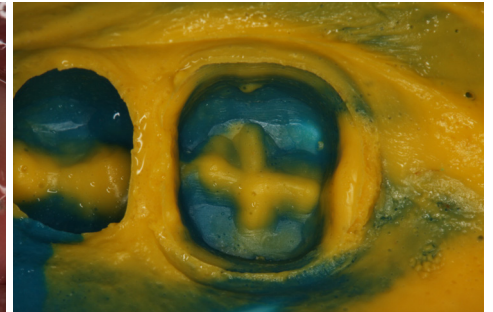


PHOTO #3

### PHOTO #3

- ↖ Final impression using **Honigum Pro QuadFast**