Is there still a justification for the analog technique in implant-supported temporary restorations?

Dr. Stefan Koubi DDS PhD

INTRODUCTION

The use of implants in everyday dental practice has become very popular in the last two decades due to the simplification of the procedure and accessibility of the technique for the general practitioner.

The use of implants with immediate placement and loading has also proven to be a reliable solution, dependent upon the clinical indication and situation.

The patient's general health, including mental attitude, is the key to successful acceptance of the treatment plan by the patient.

If the dentist is able to remove the tooth, place an implant, and fabricate correctly fitting, esthetic temporary restorations on the same day, then we consider this a complete success from the patient's and the dentist's point of view.

Making good temporary restorations on the same day is still a challenge for the cooperation between dentist and dental technician due to the tight time schedule, the customary high esthetic expectations and the mechanical properties of the material, which is intended to remain in the mouth for at least 6 months.

In the meantime, digital technology has made it possible to produce printed surgical templates and printed or milled temporary restorations that can be attached to the implant. These technological advances are already functioning very well and will become more and more frequent in the future.

Nevertheless, the economic reality of dental practices has changed considerably over the last 5 years and it is easy to see that the technological promise does not always align with the economic reality. The digital workflow is still more expensive, no matter what the expert can use as an argument.

The purpose of this article is to present a simple and cost-effective way of producing good, esthetic, implant-supported temporary restorations with an analog procedure that takes economic reality into account.

Fig. 1: Initial situation after implant placement

Fig. 2: Wax-up with gum reproduction



Fig. 3: Silicone key with Honigum Light

CASE STUDY

5 implants (V3 MIS NP) were placed with immediate loading after tooth extraction in a 56-year-old female patient with severe apical infection under a tooth-supported restoration at 22, 21 and 12. We were not able to place the implant ideally for 22 because there is a severe bone deficit and it is impossible to construct an angled multi-unit abutment on an implant with a narrow platform. The dental arch is very narrow, and the amount of bone material is very low. The treatment plan is as follows:

- Implant-supported restoration from 15 to 22
- Tooth supported restoration from 23 to 27

A wax-up is made to restore the lip support and a beautiful contour of the smile (Fig. 2). The teeth are designed according to the patient's wishes (the teeth are very white and have been aligned without too much individualization).

In order to maintain an ideal tooth proportion and to counteract the strong bone resorption, a gum substitute is used in the cervical area of the front teeth.

A silicone putty index made of putty material (lab silicone, Henry Schein) is lined with easy-flowing precision silicone (Honigum-Light, DMG) to obtain a precise reproduction of the texture (Fig. 3).

After the accuracy of the fit is checked, a reinforced bis-acrylic composite (LuxaCrown, DMG) is injected into the silicone index. The injection must be done from the underside of the incisal edge to the cervical area.

After the setting time (05:00 minutes) the silicone index is removed (Fig. 4). Small bubbles may appear in the incisal edge area and also in the anterior region. This depends on the insertion and pressure of the silicone index (it is important not to allow any movement of the silicone index during the setting time) and on the injection of the material into the silicone index. This small bubble can be filled with a drop of flowable composite (LuxaFlow Ultra, DMG) or it can be filled with more LuxaCrown before starting polishing.

Pink composite (Gradia Pink, GC) is applied to the cervical area and the polishing work begins (Fig. 5).

For primary polishing, silicone discs with a high grain size are used to finalize the shape (Fig. 6).

White and pink composites are polished with the same material. This only takes a few minutes. Then a universal polishing paste is applied to the surface to achieve a shiny effect (Fig. 7).

The use of the diamond paste significantly improves the surface texture due to the chemical composition of LuxaCrown.

High-gloss polishing using mini polishing brushes (HATHO) only with then without polishing paste. The brightness and texture are easily optimized with this simple polishing technique (Fig. 9).

Intra-oral cementation of temporary restorations for both implant-supported and tooth-supported restorations (Fig. 10).

Occlusal view of both temporary restorations before closing the access to the screws and relining the tooth-supported temporary restoration (Fig. 11).

View of the temporary restoration after 6 months, before placement of the definitive ceramic restoration (Fig. 12).

Restoration with implant-supported restorations made of ceramics (Fig. 13).

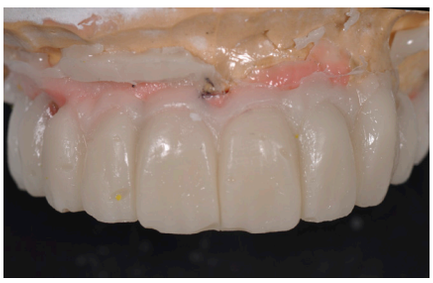

Fig. 4: Restoration directly after removal of the silicone key

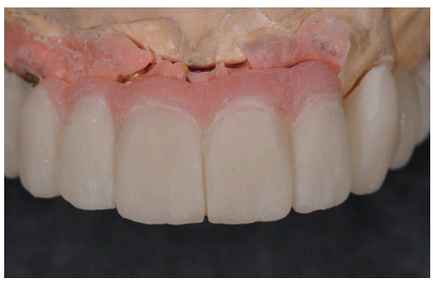

Fig. 5: Restoration after gingival mask has been added

Fig. 6: Pre-polishing

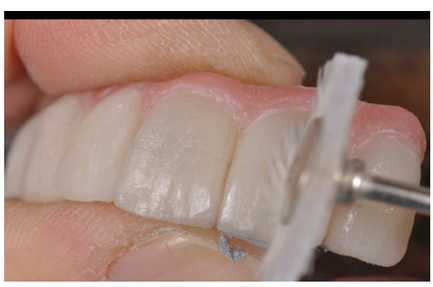

Fig. 7: Polishing with polishing paste

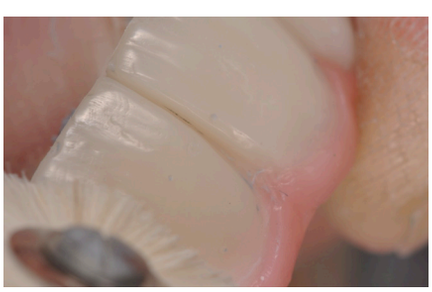

Fig. 8: High-gloss polishing

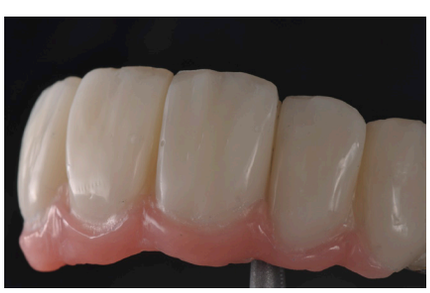

Fig. 9: LuxaCrown restoration after polishing

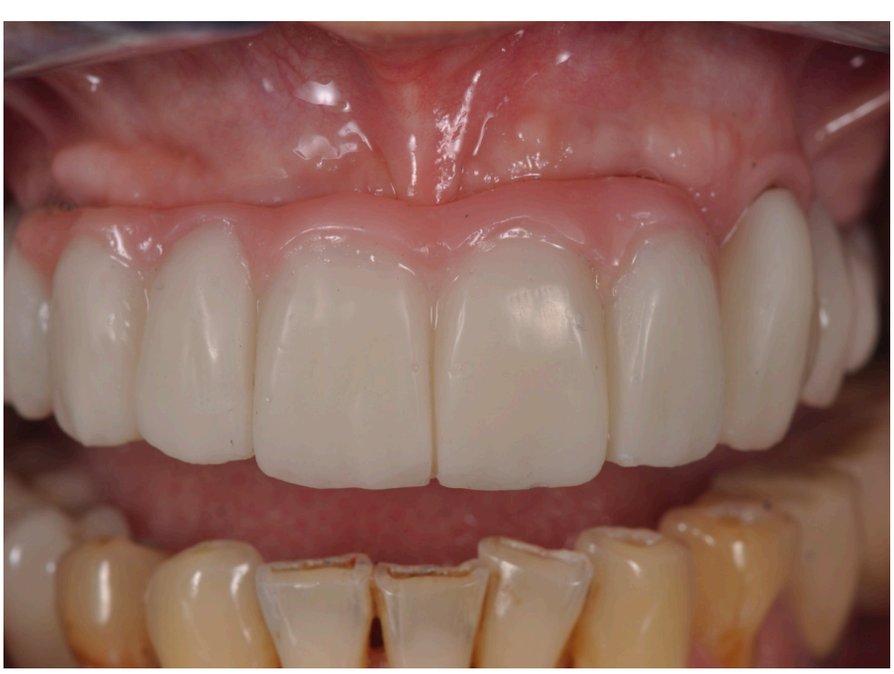

Fig. 10: Integration of the restorations

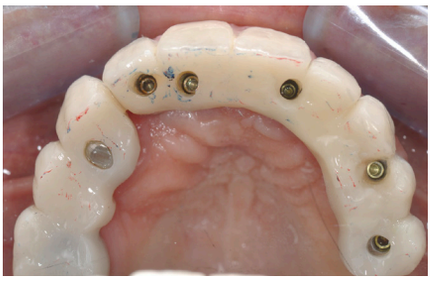

Fig. 11: Occlusal view

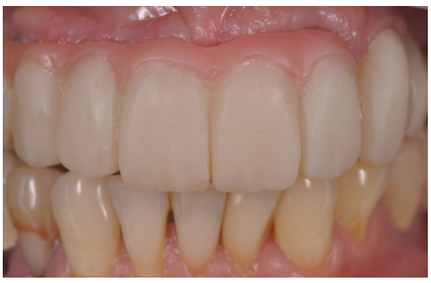

Fig. 12: LuxaCrown restoration after 6 months

Fig. 13: Final ceramic restoration

CONCLUSION

The aim of the article was to provide simple tips and tricks within the realm of economic reality and that are useful in everyday dental practice.

The analog approach presented here is efficient in various respects:

- Fast
- Technically tried and tested
- Esthetic

The digital option with other materials is also a useful method for the dentist, but it costs more and can take longer. Our aim is not to let the two options compete against each other, but simply to identify the advantages and weaknesses of each technique.
The challenge for the dentist is not to choose one of the two techniques, but to try to find the best combination of analog and digital workflows and get the best out of both options.

LITERATURE REFERENCES:

Ostman PO1, Hellman M, Sennerby L, Wennerberg A.
Temporary implant-supported prosthesis for immediate loading according to a chair-side concept: technical note and results from 37 consecutive cases.
Clin Implant Dent Relat Res. 2008 May;10(2):71-7.

Cooper L1, De Kok IJ, Reside GJ, Pungpapong P, Rojas-Vizcaya F.
Immediate fixed restoration of the edentulous maxilla after implant placement.
J Oral Maxillofac Surg. 2005 Sep;63(9 Suppl 2):97-110.

CONTACT:

Dr. Stefan Koubi, DDS, PhD
51 B Rue Saint Sebastien
13006 Marseille
France